

# A CASE REPORT OF PARENTAL TRANSMISSION OF KOOLEN-DE VRIES SYNDROME

RENDEIRO P<sup>1</sup>, GONÇALVES R<sup>2</sup>, FREIXO JP<sup>2</sup>, LEMOS R<sup>1</sup>, VENTURA C<sup>1</sup>, PEREIRA SM<sup>1</sup>, DE ALMEIDA S<sup>1,2</sup>, TAVARES P<sup>1</sup>, PINTO-BASTO J<sup>1</sup>, SÁ J<sup>1</sup>

<sup>1</sup> CYTOGENETICS LABORATORY, CGC GENETICS - PORTO, PORTUGAL

<sup>2</sup> DEPARTMENT OF MEDICAL GENETICS, HOSPITAL DONA ESTEFÂNIA - CHLC EPE, LISBON, PORTUGAL

## BACKGROUND

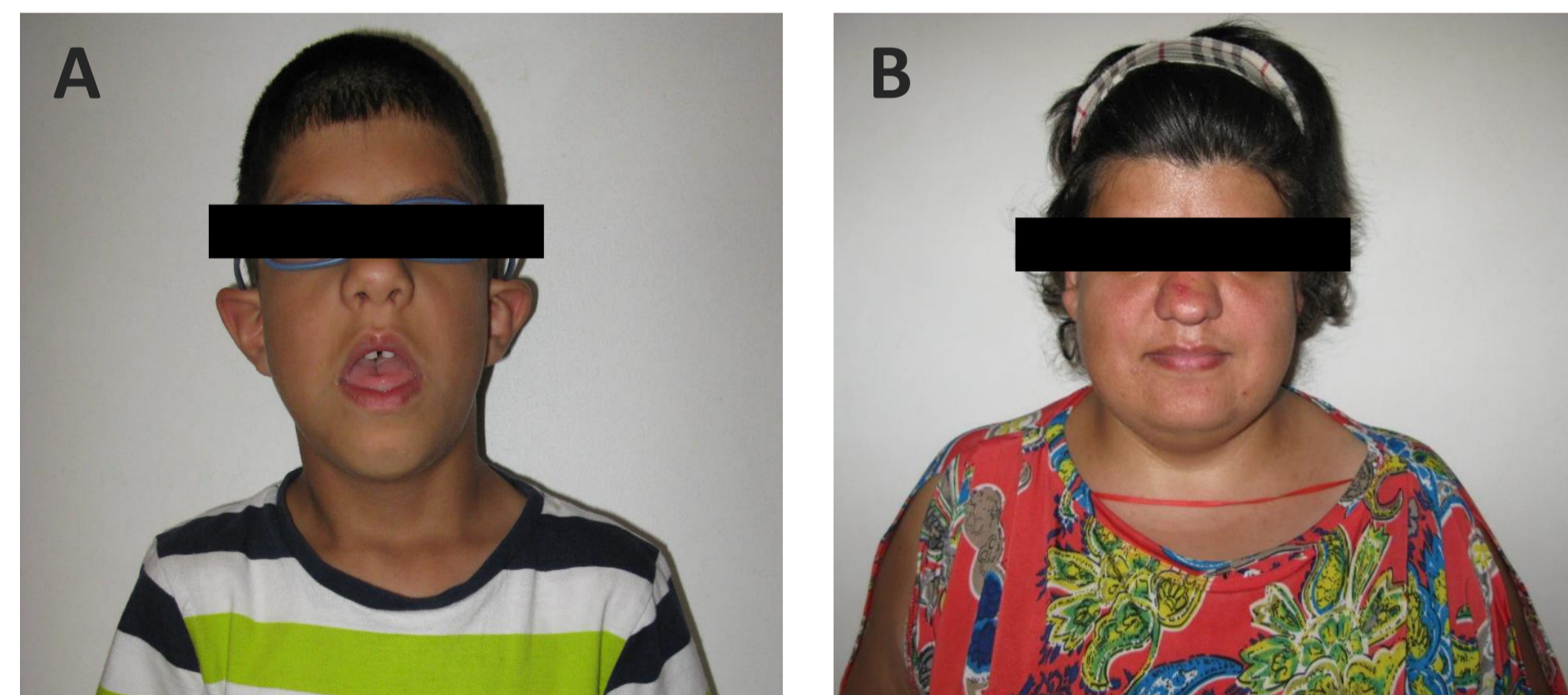
Koolen-De Vries Syndrome (KDVS) is a rare disorder caused by haploinsufficiency of *KANSL1* gene, either by heterozygous mutation of *KANSL1* or microdeletion on chromosome 17q21.31. It is estimated that the prevalence of this syndrome in the population is 1 in 16000 people. Major clinical features include delayed psychomotor development, hypotonia, characteristic facial features (Koolen *et al.* 2006, Koolen *et al.* 2008, Tan *et al.* 2009). To this day, all individuals reported with KDVS were identified as having the syndrome as a result of a *de novo* microdeletion/mutation event. Even though it is not known whether KDVS affects fertility, it is considered that parent-to-offspring transmission can take place in an autosomal dominant manner. However, no individual with KDVS has been reported to have had children of their own.

We report two novel patients with KDVS, in which the microdeletion pattern associated with this syndrome was vertically transmitted, from mother to son. To our knowledge this is the first case report of a parental transmission of KDVS. Informed consent was obtained prior to case report publication.

## CASE REPORT

### CLINICAL REPORT

The proband (Fig 1A, Table I) is a 9yo male and is the firstborn child of Caucasian non-consanguineous parents. Proband was born after 34 weeks of gestation by caesarean section due to abnormal fluxometry. Birth weight and length were 1805g (10<sup>th</sup> percentile) and 39cm (<3<sup>rd</sup> percentile), respectively. The Apgar score was 3 and 8, at 1 and 5 min, respectively. He was extubated at 4 min of life. A mild global hypotonia led to feeding difficulties, which was resolved by the end of the neonatal period and feeding autonomy was acquired. The mother of the proband (Fig 1B, Table I) is 33 years of age, has a mild short stature (151 cm) and mild developmental delay, which lead to the suspicion of being a carrier of the same genetic syndrome as her son.



**Figure 1.** Clinical photographs of patients, demonstrating clinical phenotype of KDVS. Proband (A) at 9 years of age showing several characteristic features such as long face, prominent ears, blepharophimosis, pear-shaped nose, frequently open mouth, strabismus and marked sulcus in the tongue. Proband's mother (B) at 33 years of age presenting a long columella, hypoplastic alae nasi with bulbous nasal tip and a broad chin.

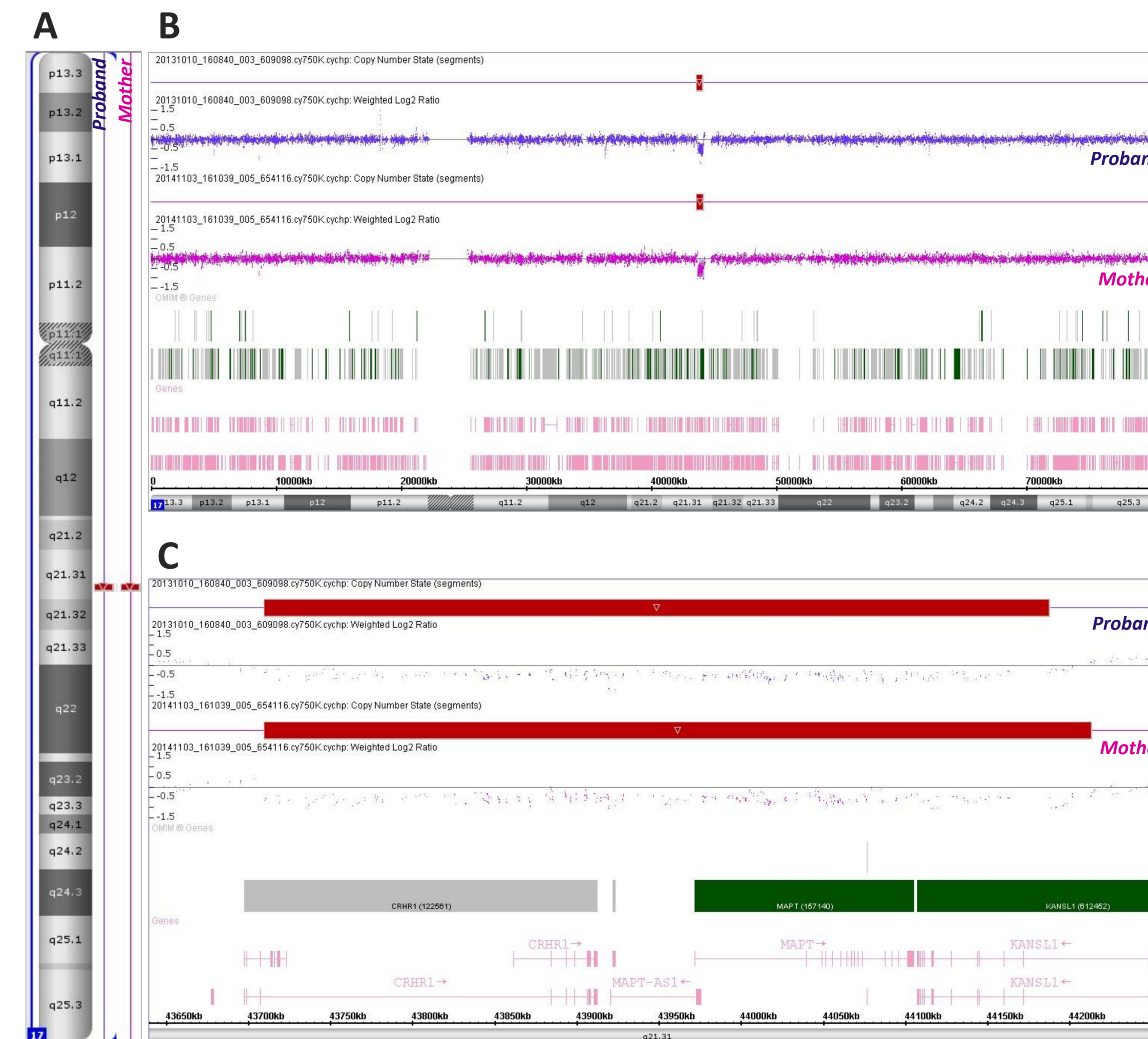**Table I.** Clinical features from patients with KDVS classified as absent (-), mild (+), moderate (++) or severe (+++) or unknown.

|                         | Clinical information                      | Classification |         |
|-------------------------|---|----------------|---------|
|                         |   | Proband        | Mother  |
| <b>Main Features</b>    | Low birth weight                          | +++            | unknown |
|                         | Microcephaly                              | ++             | unknown |
|                         | Short stature                             | +              | +       |
|                         | Developmental delay                       | ++             | ++      |
|                         | Hypotonia                                 | ++             | unknown |
| <b>Facial</b>           | Expressive language delay                 | ++             | +       |
|                         | Nasal speech                              | +              | +       |
|                         | Long face                                 | ++             | +       |
|                         | Ptosis                                    | ++             | ++      |
|                         | Blepharophimosis                          | ++             | +       |
|                         | Large/prominent ears                      | ++             | +       |
|                         | Tubular or pear-shaped nose               | ++             | ++      |
|                         | Bulbous nasal tip                         | ++             | ++      |
|                         | Long columella, hypoplastic alae nasi     | ++             | ++      |
|                         | Narrow/high palate                        | ++             | +       |
| <b>Ocular</b>           | Broad chin                                | +              | ++      |
|                         | Upward-slanting palpebral fissures        | -              | +       |
|                         | Highly marked median sulcus of the tongue | ++             | unknown |
|                         | Frequently open mouth                     | +++            | +       |
|                         | Strabismus                                | ++             | unknown |
| <b>Body/Extremities</b> | Hip dislocation/dysplasia                 | -              | ++      |
|                         | Positional deformity feet                 | ++             | +       |
|                         | Hallux valgus                             | +              | unknown |
|                         | Pes cavus                                 | ++             | unknown |
| <b>Spine</b>            | Sagittal synostosis                       | ++             | +       |
|                         | Kyphosis                                  | +              | +       |
| <b>Kidney/Urologic</b>  | Cryptorchidism                            | ++             | -       |
|                         | Abnormal hair color/texture               | ++             | ++      |
| <b>Ectodermal</b>       | Dental abnormalities                      | +              | +       |
|                         | Conductive hearing loss                   | -              | +       |
| <b>Additional</b>       | Friendly, amiable behavior                | ++             | ++      |
|                         | Joint hypermobility                       | ++             | ++      |
|                         | Persistent fetal fingertip pads           | +              | -       |
|                         | Behavioral problems                       | +              | +       |

## GENETIC REPORT

Proband was initially tested for a genetic disorder by chromosome analysis (karyotyping), fragile X syndrome (*FMR1* gene, msTP-PCR) and FISH with subtelomeric probes, all with normal results. At age 7, a chromosomal microarray analysis (array CGH) was performed on an Affymetrix platform, Cytoscan 750K. Data analysis was performed using ChAS Software, Affymetrix (NCBI\_hg19 reference). Array CGH revealed a 477 Kb interstitial microdeletion at 17q21.31 (Chr17:43,710,150-44,187,492) and KDVS diagnosis was concluded.

The mother of the proband was studied at age 32, after the son diagnosis, by array CGH and a 503 Kb interstitial microdeletion at 17q21.31 (Chr17:43,710,150-44,213,434) was found and diagnosis was also concluded as KDVS. Results from array CGH are shown in Figure 2 and deleted genes are detailed in Table II.



**Figure 2.** Array CGH results from proband and his mother. (A) view of chromosome 17 ideogram with focus on 17q21.31 microdeletion location; (B) view of oligonucleotides profiles over the entire chromosome 17 and (C) detailed view of the deletions, specifying affected genes.

**Table II.** Detail of genes involved in 17q21.31 microdeletion, according to databases such as UCSC, OMIM and UniProtKB. In bold are highlighted two genes known to be involved in human disease.

| Gene symbol (OMIM)     | Gene Name                                  | Gene Function  | Expression       |
|------------------------|--|--|------------------|
| <b>CRHR1 (122561)</b>  | Corticotropin releasing hormone receptor 1 | Activation of signal transduction pathways that regulate diverse physiological processes including stress, reproduction, immune response and obesity   | Multiple tissues |
| <b>SPPL2C (608284)</b> | Signal peptide peptidase like 2C           | Intramembrane-cleaving aspartic protease (I-CLiP) that may be able to cleave type II membrane signal peptides in the hydrophobic plane of the membrane | Ubiquitous       |
| <b>MAPT (157140)</b>   | Microtubule-associated protein tau         | <b>Promotes microtubule assembly and stability, and might be involved in the establishment and maintenance of neuronal polarity</b>                    | CNS              |
| <b>MAPT-IT1</b>        | MAPT intronic transcript 1                 | -  | -                |
| <b>STH (607067)</b>    | Saitohin                                   | Unknown  | Multiple tissues |
| <b>KANSL1 (612452)</b> | KAT8 regulatory NSL complex subunit 1      | Subunit of two protein complexes involved with histone acetylation (MLL1 complex and NSL1 complex)   | Brain            |

Both microdeletions resulted in complete loss of 9 genes, of which *KANSL1* and *MAPT* are known to be associated to human disease. Other protein and non-protein genes are unknown or have not been related to human disease and, therefore, it is unclear to which extent they are involved in the clinical phenotype.

## CONCLUSION

We report for the first time a case of parental transmission of KDVS, from mother to son, confirming its autosomal dominant inheritance pattern. This study shows therefore the importance of studying 1<sup>st</sup> degree relatives in syndromic conditions with a clear genetic etiology. Future studies will be focused on testing further members of the family to investigate the origin of the microdeletion pattern.

## REFERENCES

- Koolen, DA *et al.* (2008) Clinical and molecular delineation of the 17q21.31 microdeletion syndrome. *Journal of medical genetics*, 45, 710-720.  
 Koolen, DA *et al.* (2006) A new chromosome 17q21.31 microdeletion syndrome associated with a common inversion polymorphism. *Nat Genet*, 38, 999-1001.  
 Tan, TY, *et al.* (2009) Phenotypic expansion and further characterization of the 17q21.31 microdeletion syndrome. *Journal of Medical Genetics*, 46, 480-489.